



Chapter 44

Care of the Patient with a Musculoskeletal Disorder

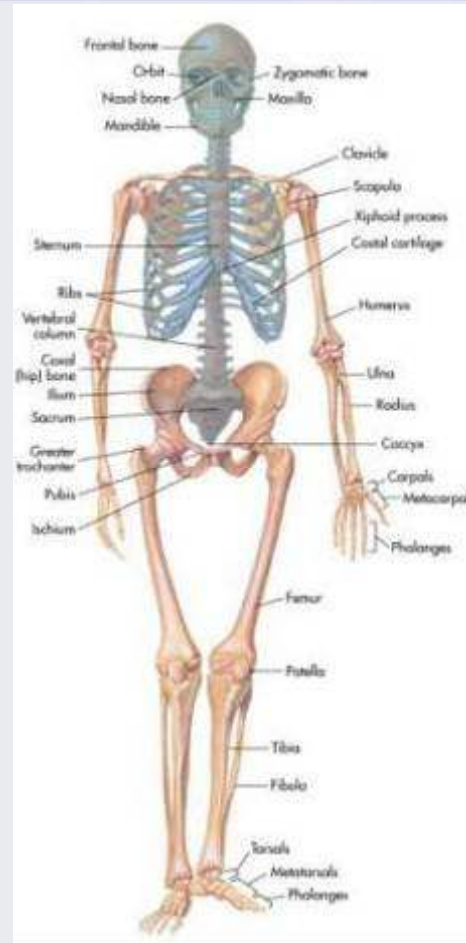

Overview of Anatomy and Physiology

- Functions of the skeletal system
 - Support
 - Protection
 - Movement
 - Mineral storage
 - Hemopoiesis
- Structure of bones
 - Four classifications based on form and shape
 - Long, short, flat, and irregular



Figure 44-2

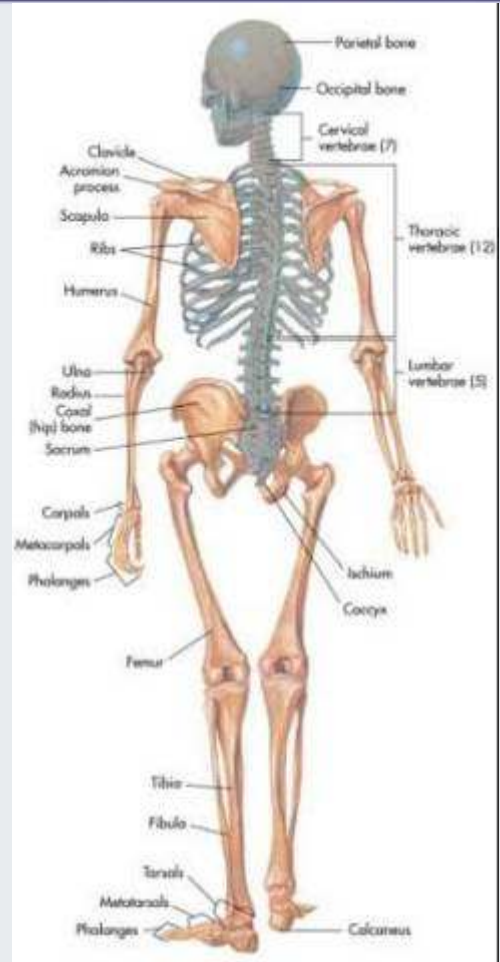

(From Thibodeau, G.A., Patton, K.T. [2005]. *The human body in health and disease*. [4th ed.]. St. Louis: Mosby.)

Skeleton, anterior view.



Figure 44-3



(From Thibodeau, G.A., Patton, K.T. [2005]. *The human body in health and disease*. [4th ed.]. St. Louis: Mosby.)

Skeleton, posterior view.

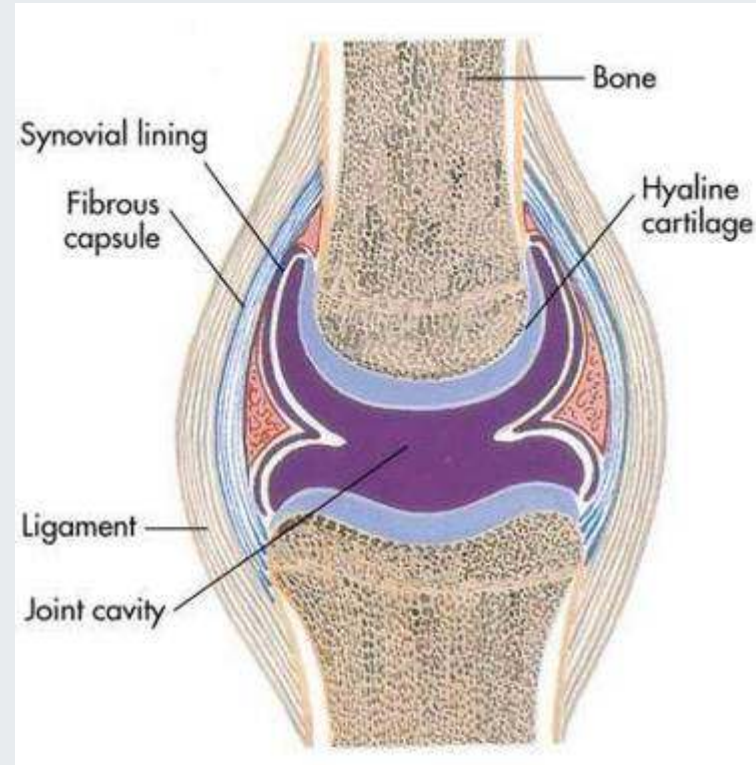

Overview of Anatomy and Physiology

- Articulations (joints)
 - Allow movement
 - Three types according to degree of movement
 - Synarthrosis—no movement
 - Amphiarthrosis—slight movement
 - Diarthrosis—free movement
- Divisions of the skeleton
 - Axial skeleton
 - Appendicular skeleton



Figure 44-1



(From Thibodeau, G.A., Patton, K.T. [2008]. *Structure and function of the body*. [13th ed.]. St. Louis: Mosby.)

Structure of a freely movable (diarthrotic) joint.

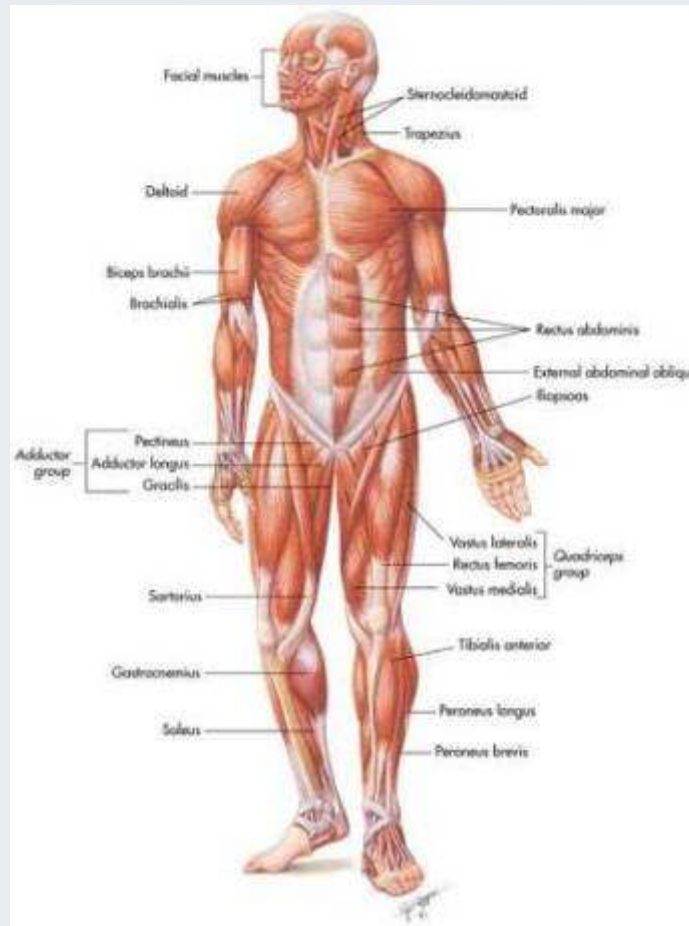


Overview of Anatomy and Physiology

- Functions of the muscular system
 - Motion
 - Maintenance of posture
 - Production of heat
- Skeletal muscle structure
 - Epimysium
 - Perimysium
 - Endomysium



Figure 44-5

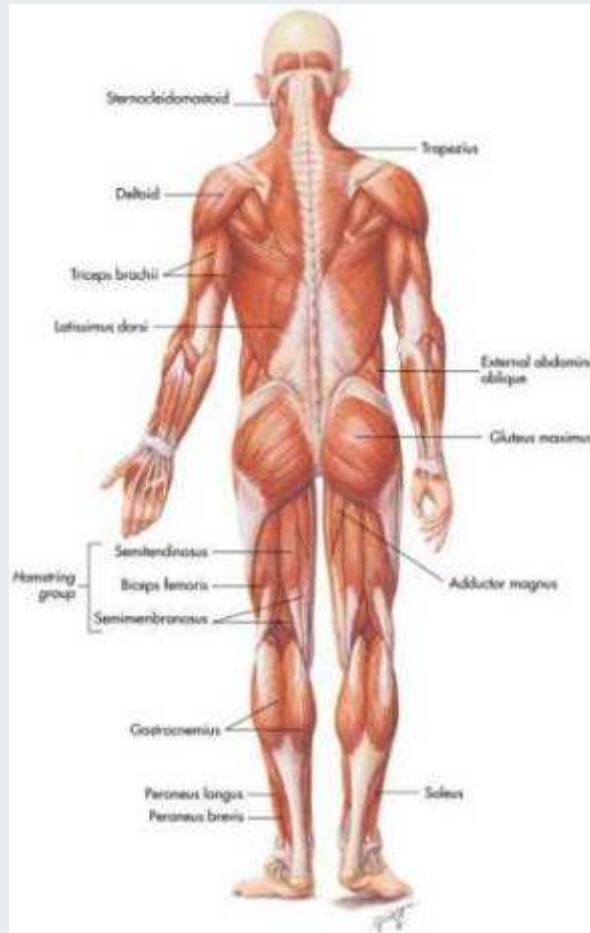

(From Thibodeau, G.A., Patton, K.T. [2005]. *The human body in health and disease*. [4th ed.]. St. Louis: Mosby.)

Anterior view of the body.



Figure 44-6



(From Thibodeau, G.A., Patton, K.T. [2005]. *The human body in health and disease*. [4th ed.]. St. Louis: Mosby.)

Posterior view of the body.



Overview of Anatomy and Physiology

- Nerve and blood supply
 - Blood vessels provide a constant supply of oxygen and nutrition, and nerve cells/fibers supply a constant source of information
- Muscle contraction
 - Muscle stimulus—when a muscle cell is adequately stimulated, it will contract
 - Muscle tone—skeletal muscles are in a constant state of readiness for action
 - Types of body movements—flexion, extension, abduction, adduction, rotation, supination, pronation, dorsiflexion, and plantar flexion



Laboratory and Diagnostic Examinations

- Radiographic studies
 - Myelogram
 - Nuclear scanning
 - Magnetic resonance imaging (MRI)
 - Computed axial tomography (CT or CAT scan)
 - Bone scan
- Endoscopic examination
 - Arthroscopy
 - Endoscopic spinal microsurgery



Laboratory and Diagnostic Examinations

- Aspiration
 - Synovial fluid aspiration
- Electrographic procedure
 - Electromyogram (EMG)
- Laboratory tests
 - Calcium
 - Erythrocyte sedimentation rate (ESR)
 - Lupus erythematosus (LE) preparation
 - Rheumatoid factor (RF)
 - Uric acid (blood)



Inflammatory Disorders of the Musculoskeletal System

- Rheumatoid arthritis
 - Etiology/pathophysiology
 - Most serious form of arthritis
 - Chronic, systemic disease
 - Most common in women of childbearing age
 - Autoimmune disorder, but may also be genetic
 - May affect lungs, heart, blood vessels, muscles, eyes, and skin
 - Chronic inflammation of the synovial membrane of the diarthrodial joints (movable)

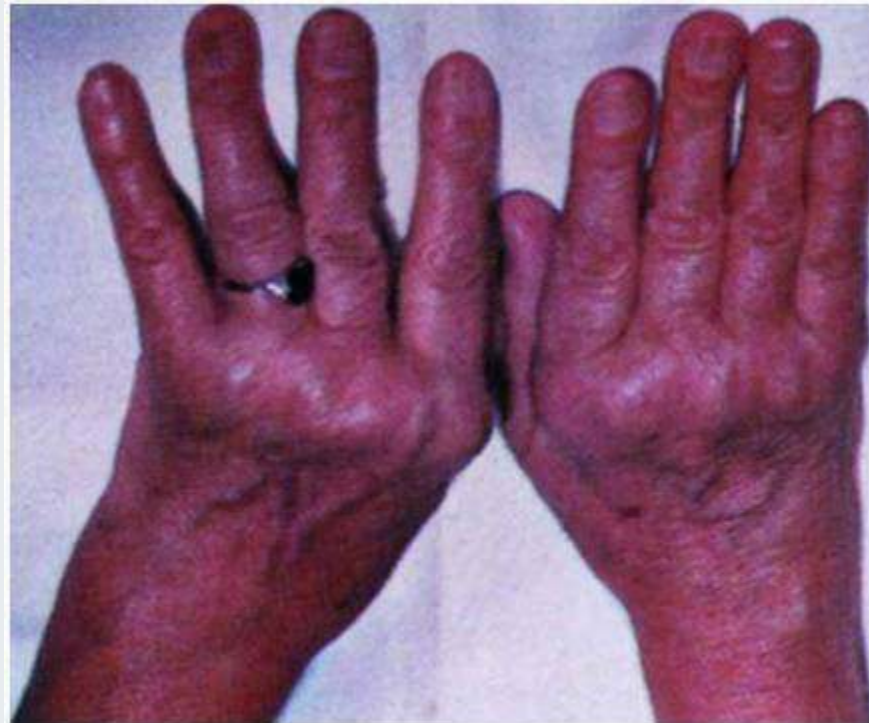

Inflammatory Disorders of the Musculoskeletal System

- Rheumatoid arthritis (*continued*)
 - Clinical manifestations/assessment
 - Characterized by periods of remission and exacerbation
 - Malaise
 - Muscle weakness
 - Loss of appetite
 - Generalized aching
 - Edema and tenderness of joints
 - Limited range of motion (morning stiffness)



Figure 44-7



(From Kamal, A., Brocklehurst, J.C. [1991]. *Color atlas of geriatric medicine*. [2nd ed.]. St. Louis: Mosby.)

Rheumatoid arthritis of hands.



Inflammatory Disorders of the Musculoskeletal System

- Rheumatoid arthritis (*continued*)
 - Diagnostic tests
 - Radiography studies show loss of articular cartilage and change in bone structure
 - Laboratory tests
 - Erythrocyte sedimentation rate (ESR)
 - Rheumatoid factor (RF)
 - Latex agglutination test
 - Synovial fluid aspiration



Inflammatory Disorders of the Musculoskeletal System

- Rheumatoid arthritis (*continued*)
 - Medical management/nursing interventions
 - Pharmacological management
 - Salicylates, NSAIDs, COX-2 inhibitors, anti-inflammatory agents, disease-modifying antirheumatoid drugs
 - Rest: 8 to 10 hours of sleep a night
 - Exercise: Range of motion two to three times per day
 - Heat: Hot packs, heat lamp, and/or hot paraffin
 - Rehabilitation



Inflammatory Disorders of the Musculoskeletal System

- Ankylosing spondylitis
 - Etiology/pathophysiology
 - Chronic, progressive disorder of the sacroiliac and hip joints, the synovial joints of the spine, and the adjacent soft tissues
 - Most common in young men
 - Strong hereditary tendency
 - Clinical manifestations/assessment
 - Pain and stiffness in back; decreased ROM
 - Elevated temperature; tachycardia; hyperpnea



Inflammatory Disorders of the Musculoskeletal System

- Ankylosing spondylitis (*continued*)
 - Diagnostic tests
 - Hemoglobin, hematocrit, ESR, alkaline phosphatase
 - Radiographic
 - Medical management/nursing interventions
 - Pharmacological management
 - Analgesics, NSAIDs
 - Exercise program: swimming and walking
 - Surgery: replace fused joints
 - Maintain spine alignment
 - Turn, position, and breathing exercises every 2 hours

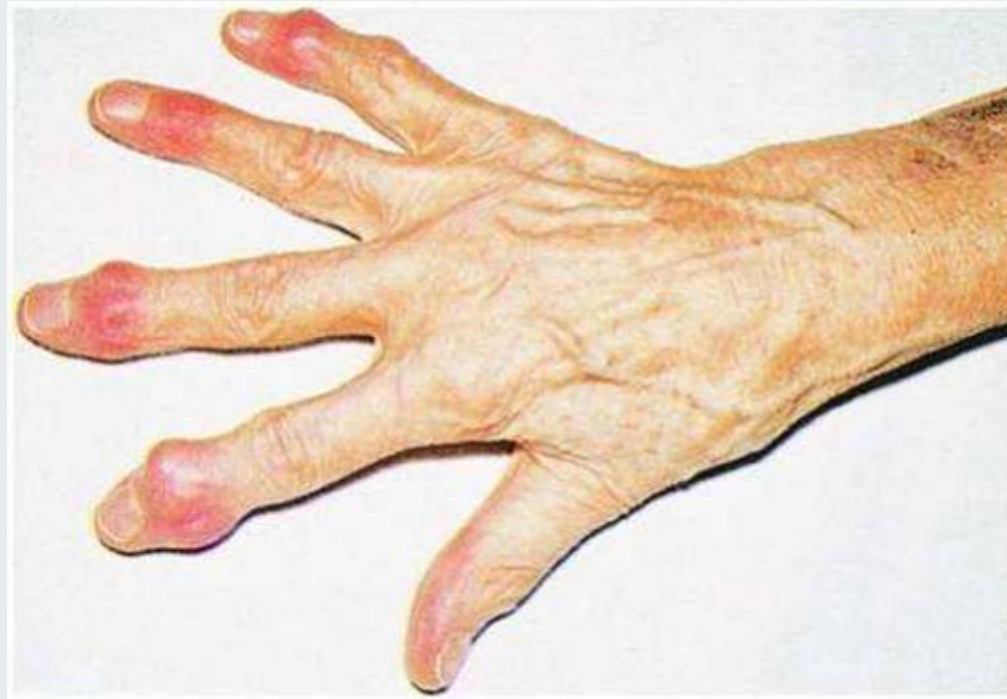

Inflammatory Disorders of the Musculoskeletal System

- Osteoarthritis (degenerative joint disease)
 - Etiology/pathophysiology
 - Nonsystemic, noninflammatory disorder that progressively causes bones and joints to degenerate
 - Primary
 - Cause is unknown
 - Secondary
 - Caused by trauma, infections, previous fractures, rheumatoid arthritis, stress on weight-bearing joints



Figure 44-9



(From Kamal, A., Brocklehurst, J.C. [1991]. *Color atlas of geriatric medicine*. [2nd ed.]. St. Louis: Mosby.)

Heberden's nodes.



Inflammatory Disorders of the Musculoskeletal System

- Osteoarthritis (degenerative joint disease)
(continued)
 - Clinical manifestations/assessment
 - Joint edema, tenderness, instability, and deformity
 - Heberden's nodes
 - Bouchard's nodes
 - Diagnostic tests
 - Radiographic studies
 - Arthroscopy
 - Synovial fluid examination
 - Bone scans



Inflammatory Disorders of the Musculoskeletal System

- Osteoarthritis (degenerative joint disease) (*continued*)
 - Medical management/nursing interventions
 - Pharmacological management
 - Salicylates, NSAIDs, corticosteroids, glucosamine supplements
 - Exercise balanced with rest
 - Heat applications
 - Gait enhancers (canes, walkers, etc.)
 - Surgery
 - Osteotomy
 - Joint replacement



Inflammatory Disorders of the Musculoskeletal System

- Gout (gouty arthritis)
 - Etiology/pathophysiology
 - Metabolic disease resulting from an accumulation of uric acid in the blood
 - Caused by an ineffective metabolism of purines
 - Primary: hereditary factors
 - Secondary: use of certain drugs, complication of other diseases, or idiopathic
 - Affects men more frequently than women
 - Does not occur before puberty in males or before menopause in females



Inflammatory Disorders of the Musculoskeletal System

- Gout (gouty arthritis) (*continued*)
 - Clinical manifestations/assessment
 - Excruciating pain
 - Edema
 - Inflammation (most common in the great toe)
 - Tophi
 - Diagnostic tests
 - Serum and uric acid level, CBC, ESR
 - Radiography studies
 - Synovial fluid aspiration



Inflammatory Disorders of the Musculoskeletal System

- Gout (gouty arthritis) (*continued*)
 - Medical management/nursing interventions
 - Pharmacological management
 - Colchicine, phenylbutazone (Butazolidin), indomethacin (Indocin), corticosteroids, allopurinol (Zyloprim), sulfinpyrazone (Anturane)
 - Encourage fluid intake
 - Monitor intake and output
 - Bed rest and joint immobilization
 - Dietary restrictions



Other Disorders of the Musculoskeletal System

- Osteoporosis
 - Etiology/pathophysiology
 - Reduction of bone mass
 - Most common in women ages 55 to 65
 - Contributing factors: immobilization; steroids; high intake of caffeine; diet low in calcium, high in protein; smoking; sedentary lifestyle
 - Clinical manifestations/assessment
 - Backache
 - Porous and brittle bones
 - Dowager's hump



Other Disorders of the Musculoskeletal System

- Osteoporosis (*continued*)
 - Diagnostic tests
 - CBC, serum calcium, phosphorus, alkaline phosphatase, blood urea nitrogen, creatinine level, urinalysis, liver and thyroid function tests
 - Radiography studies
 - Medical management/nursing interventions
 - Pharmacological management
 - Calcium supplements, vitamin D
 - Estrogen, alendronate (Fosamax)
 - Weight-bearing exercises
 - Dietary recommendations



Other Disorders of the Musculoskeletal System

- Osteomyelitis
 - Etiology/pathophysiology
 - Local or generalized infection of the bone and bone marrow
 - Staphylococci are the most common cause
 - Introduced through trauma (injury or surgery) or via the bloodstream from another site in the body to the bone
 - Bacteria invade the bone and degeneration of bone occurs



Other Disorders of the Musculoskeletal System

- Osteomyelitis (*continued*)
 - Clinical manifestations/assessment
 - Persistent, severe, and increasing bone pain
 - Wound draining purulent fluid
 - Signs and symptoms of infection: temperature, tachycardia, and tachypnea
 - Edema of affected area
 - Diagnostic tests
 - Radiography studies; bone scan
 - CBC; ESR; cultures of blood and drainage



Other Disorders of the Musculoskeletal System

- Osteomyelitis (*continued*)
 - Medical management/nursing interventions
 - Pharmacological management
 - Antibiotic therapy
 - Surgery: removal of necrotic bone
 - Absolute rest of affected extremity
 - Wound care
 - Irrigate with hydrogen peroxide or antibiotic solution; cover with sterile dressing
 - Drainage and secretion precautions
 - Dietary recommendations: high in calories, protein, and vitamins



Other Disorders of the Musculoskeletal System

- Fibromyalgia syndrome (FMS)
 - Etiology/pathophysiology
 - Musculoskeletal chronic pain syndrome
 - Unknown etiology
 - Clinical manifestations/assessment
 - Generalized aching
 - Irritable bowel syndrome
 - Tension headache
 - Paresthesia of upper extremities
 - Sensation of edematous hands



Other Disorders of the Musculoskeletal System

- Fibromyalgia syndrome (FMS) (*continued*)
 - Diagnostic tests
 - No specific laboratory or radiographic tests diagnose FMS
 - Medical management/nursing interventions
 - Pharmacological management
 - Tricyclic antidepressants
 - Patient education and reassurance
 - Exercise
 - Relaxation techniques

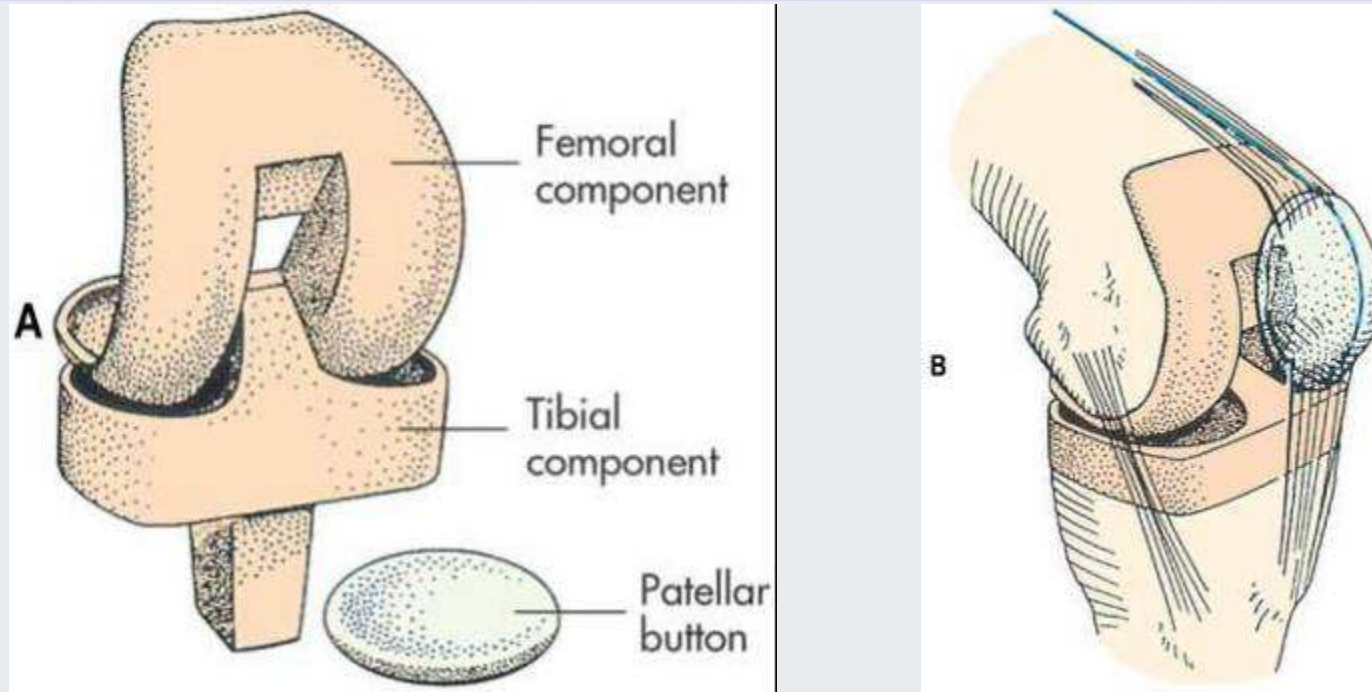


Surgical Interventions for Total Knee or Total Hip Replacement

- Knee arthroplasty (total knee replacement)
 - Replacement of the knee joint
 - Restore motion of the joint, relieve pain, or correct deformity
- Hip arthroplasty (total hip replacement)
 - Replacement of the hip joint



Figure 44-11

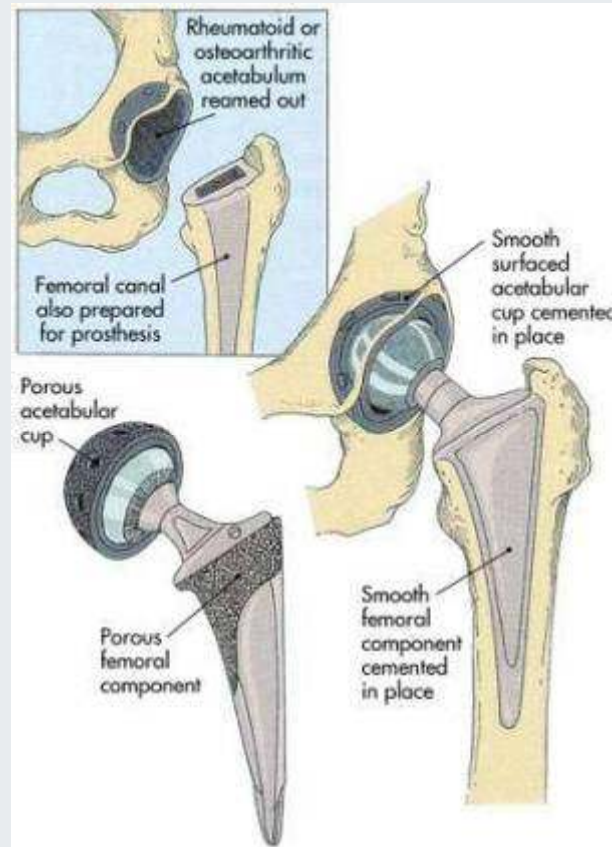


(from Monahan, F.D., et al. [2007]. Phipps' *medical-surgical nursing: health and illness perspectives*. [8th ed.]. St. Louis: Mosby.)

A, Tibial and femoral components of total knee prosthesis. **B**, Total knee prosthesis in place.



Figure 44-14



Hip arthroplasty (total hip replacement).



Surgical Interventions for Total Knee or Total Hip Replacement

- Arthroplasty
 - Nursing interventions
 - Intake and output
 - Drainage from operative drains
 - Oral and intravenous intake
 - Urinary output
 - Promote respiratory function
 - Give oxygen 2 to 3 L/min
 - Incentive spirometer; cough and deep-breathe
 - Bed rest for 24 to 48 hours
 - Change dressing as ordered
 - Diet as ordered
 - Neurovascular checks and vital signs every 4 hours



Surgical Interventions for Total Knee or Total Hip Replacement

- Arthroplasty (*continued*)
 - Nursing interventions (*continued*)
 - Physical therapy will initiate ambulation and prescribe routine
 - Antiembolism stockings
 - Avoid dislocation of prosthesis
 - Avoid adduction and hyperflexion of hip
 - Use toilet riser to prevent hyperflexion of hip

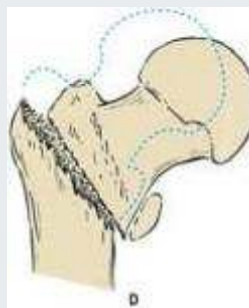
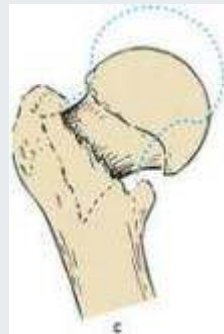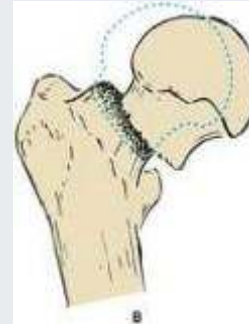

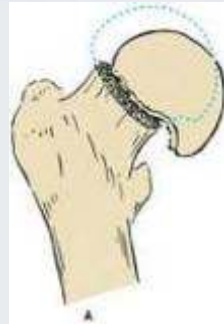
Fractures

- Fracture of the hip
 - Etiology/pathophysiology
 - Most common type of fracture
 - Women at higher risk due to osteoporosis
 - Types: intracapsular and extracapsular
 - Clinical manifestations/assessment
 - Severe pain at site
 - Inability to move the leg voluntarily
 - Shortening or external rotation of the leg



Figure 44-16



(from Monahan, F.D., et al. [2007]. Phipps' *medical-surgical nursing: health and illness perspectives*. [8th ed.]. St. Louis: Mosby.

Fractures of the hip.



Fractures

- Fracture of the hip (*continued*)
 - Diagnostic tests
 - Radiographic examination
 - Hemoglobin
 - Medical management/nursing interventions
 - Buck's or Russell's traction until surgery
 - Surgical repair
 - Internal fixation
 - Neufeld nail and screws, Kuntscher nail
 - Prosthetic implants
 - Austin Moore prosthesis, bipolar hip replacement



Fractures

- Fracture of the hip (*continued*)
 - Medical management/nursing interventions (*continued*)
 - Postoperative interventions
 - Wound and drain assessment
 - Vital signs
 - Incentive spirometer and turning every 2 hours
 - Antiembolic stockings; anticoagulation therapy
 - Maintain leg abduction
 - Limit weight-bearing on affected side
 - Chairs and commode seats should be raised to prevent flexion of hip beyond 60 degrees



Fractures

- Fracture of the hip (*continued*)
 - Medical management/nursing interventions (*continued*)
 - Patient teaching for open reduction internal fixation (ORIF)
 - Assess ability to understand
 - Assist to dangle at bedside
 - No weight on operative side
 - Turn every 2 hours, maintain abduction
 - Physical therapy will instruct as to ambulation and weight-bearing
 - As patient progresses, encourage continuing ambulation only with assistance



Fractures

- Fracture of the hip (*continued*)
 - Medical management/nursing interventions (*continued*)
 - Patient teaching for hip prosthetic implant
 - Avoid hip flexion beyond 60 degrees for approximately 10 days; beyond 90 degrees for 2 to 3 months
 - Avoid adduction of the affected leg beyond midline for 2 to 3 months (maintain abduction)
 - Maintain partial weight-bearing for approximately 2 to 3 months
 - Avoid positioning on the operative side



Fractures

- Other fractures
 - Etiology/pathophysiology
 - A traumatic injury to a bone in which the continuity of the tissue of the bone is broken
 - Pathological or spontaneous fractures
 - Types of fractures: open, closed, greenstick, complete, comminuted, impacted, transverse, oblique, spiral, Colle's, and Pott's



Fractures

- Other fractures (*continued*)
 - Clinical manifestations/assessment
 - Pain
 - Loss of normal function
 - Obvious deformity
 - Change in the curvature or length of bone
 - Crepitus (grating sound with movement)
 - Soft tissue edema
 - Warmth over injured area
 - Ecchymosis of skin surrounding injured area
 - Loss of sensation distal to injury



Fractures

- Other fractures (*continued*)
 - Diagnostic tests
 - Radiographic examination
 - Medical management/nursing interventions
 - Splinting to prevent edema
 - Body alignment
 - Elevation of body part
 - Application of cold packs, first 24 hours
 - Administration of analgesics
 - Assess for change in color, sensation, or temperature
 - Observe for signs of shock



Fractures

- Other fractures (*continued*)
 - Medical management/nursing interventions (*continued*)
 - Closed (simple)
 - Closed reduction; immobilization; traction
 - Open reduction with internal fixation device
 - Open (compound)
 - Surgical debridement and culture of wound
 - Administration of tetanus toxoid
 - Observation for signs of infection
 - Closure of wound
 - Reduction and immobilization of fracture



Fractures

- Fracture of the vertebrae
 - Etiology/pathophysiology
 - Diving accidents
 - Blows to the head or body
 - Osteoporosis
 - Metastatic cancer
 - Motorcycle and car accidents
 - Displaced fracture may place pressure on or sever the spinal cord nerves



Fractures

- Fracture of the vertebrae (*continued*)
 - Clinical manifestations/assessment
 - Pain at site of injury
 - Partial or complete loss of mobility or sensation
 - Evidence of fracture/fracture dislocation on x-ray
 - Medical management/nursing interventions
 - Stable injuries
 - Pain medication, muscle relaxants
 - Back support, brace, or cast
 - Unstable fractures
 - Traction, open reduction



Fractures

- Fracture of the pelvis
 - Etiology/pathophysiology
 - Falls, automobile accidents, crushing accidents
 - Clinical manifestations/assessment
 - Unable to bear weight without discomfort
 - Pelvic tenderness and edema
 - Signs of shock
 - Medical management/nursing interventions
 - Bed rest—More severe fractures may require surgery and/or spica or body cast

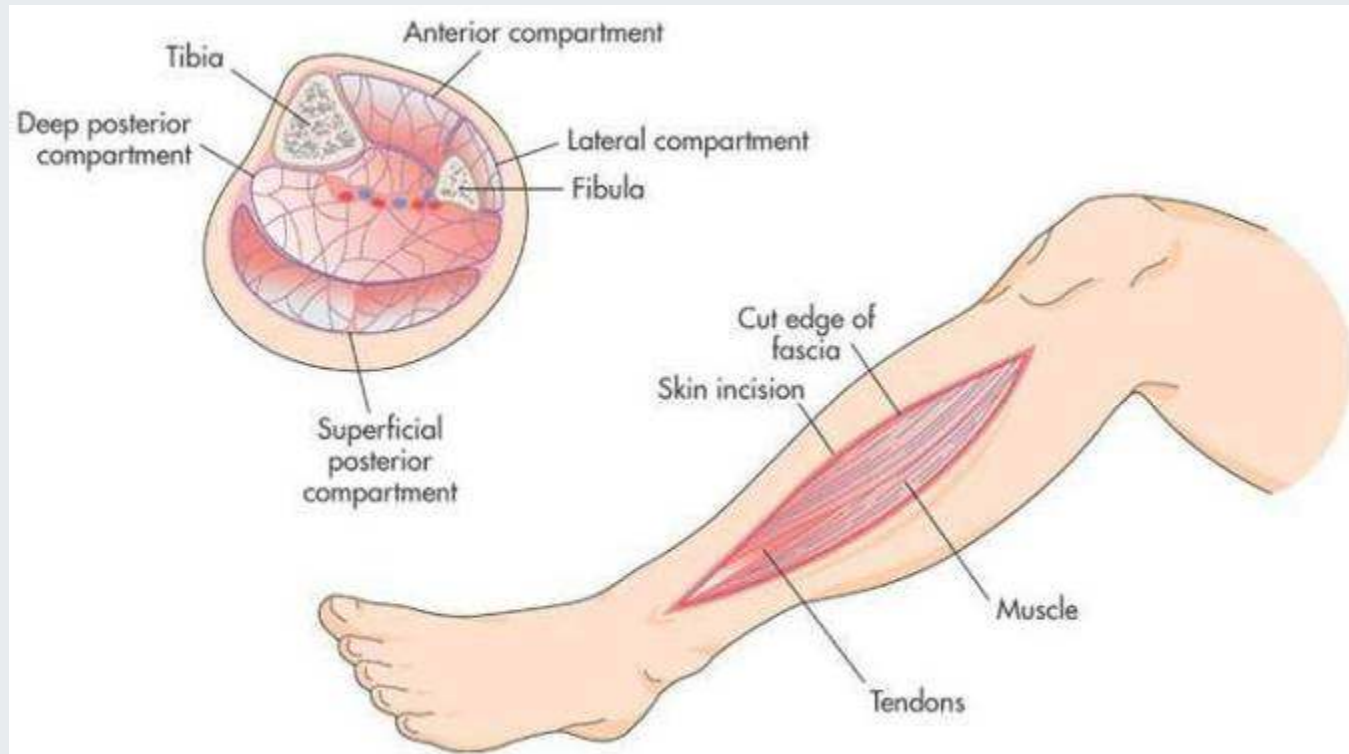


Complications of Fractures

- Compartment syndrome
 - Cause
 - Progressive development of arterial vessel compression and reduced blood supply to an extremity
 - Clinical manifestations/assessment
 - Sharp pain with movement, numbness or tingling in the affected extremity, cool and pale or cyanotic, slow capillary refill
 - Medical management/nursing interventions
 - Fasciotomy (incision into the fascia)



Figure 44-26



(From Beare, P.G., Myers, J.L. [1998]. *Adult health nursing*. [3rd ed.]. St. Louis: Mosby.)

Compartment syndrome.



Complications of Fractures

- Shock
 - Cause
 - Blood loss, pain, fear
 - Clinical manifestations/assessment
 - Altered level of consciousness, restlessness
 - Hypotension, tachycardia, and tachypnea
 - Pale, cool, moist skin
 - Medical management/nursing interventions
 - Restore blood volume; shock trousers
 - Oxygen



Complications of Fractures

- Fat embolism
 - Cause
 - Embolization of fat tissue with platelets
 - Clinical manifestations/assessment
 - Irritability, restlessness, disorientation, stupor, coma, chest pain, and dyspnea
 - Medical management/nursing interventions
 - IV fluids
 - Steroids, digoxin
 - Oxygen



Complications of Fractures

- Gas gangrene
 - Cause
 - Infection of skeletal muscle by *Clostridium*
 - Clinical manifestations/assessment
 - Pain at site of injury
 - Signs of infection; gas bubbles under the skin
 - Necrotic skin at site; foul odor from wound
 - Medical management/nursing interventions
 - Excision of gangrenous tissue
 - Antibiotics; strict aseptic technique



Complications of Fractures

- Thromboembolus
 - Cause
 - Blood vessel is occluded by an embolus
 - Clinical manifestations/assessment
 - Area tingles and is cold, numb, and cyanotic
 - Pulmonary embolus causes a sharp thoracic pain
 - Medical management/nursing interventions
 - Anticoagulants



Complications of Fractures

- Delayed fracture healing
 - Healing is delayed but will eventually occur
- Nonunion
 - The ends of the fracture fail to stabilize and heal after 6 to 9 months



Skeletal Fixation Devices

- External fixation devices
 - Skeletal pin external fixation
 - Immobilizes fractures by the use of pins inserted through the bone and attached to a rigid external metal frame
- Casts/cast brace
 - Made of layers of plaster of Paris, fiberglass, or plastic roller bandages
 - Stockinette applied, then a sheet of wadding, and casting material



Nonsurgical Interventions for Musculoskeletal Disorders

- Traction
 - The process of putting an extremity, bone, or group of muscles under tension by means of weights and pulleys to:
 - Align and stabilize a fracture site
 - Relieve pressure on nerves
 - Maintain correct positioning
 - Prevent deformities
 - Relieve muscle spasms
 - Skeletal or skin



Traumatic Injuries

- Contusion: A blow or blunt force that causes local bleeding under the skin
- Sprains: Wrenching or hyperextension of a joint
- Whiplash: Injury at cervical spine caused by hyperextension
- Strains: Microscopic muscle tears as a result of overstretching muscles and tendons



Traumatic Injuries

- Contusions, sprains, whiplash, strains
 - Medical management/nursing interventions
 - Elevate injured area
 - Cold compresses for 15 to 20 minutes intermittently for 12 to 36 hours
 - Warm compresses for 15 to 30 minutes four times a day after 24 hours
 - Compressive dressings and/or splint
 - Surgery



Traumatic Injuries

- Dislocations
 - Etiology/pathophysiology
 - Temporary displacement of bones from their normal position
 - Clinical manifestations/assessment
 - Erythema; discoloration
 - Edema
 - Pain
 - Limitation of movement
 - Deformity or shortening of the extremity



Traumatic Injuries

- Dislocations (*continued*)
 - Medical management/nursing interventions
 - Closed reduction
 - Open reduction
 - Cold compresses first 24 hours and warm compresses after 24 hours
 - Elevate injured extremity
 - Elastic bandage
 - Immobilize
 - Analgesics

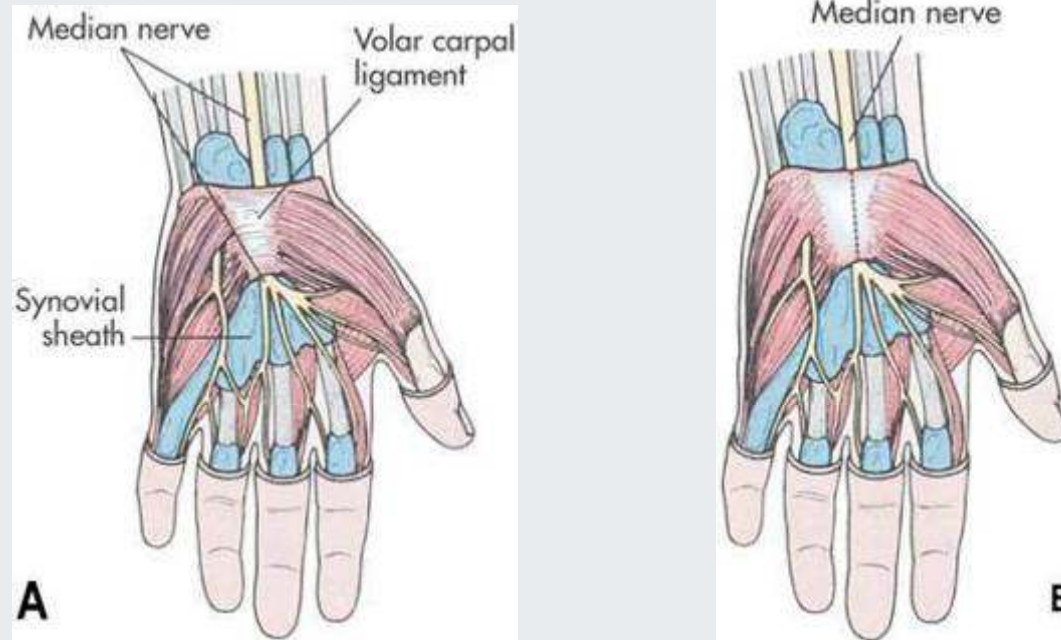


Traumatic Injuries

- Carpal tunnel syndrome
 - Etiology/pathophysiology
 - Compression of the median nerve between the carpal ligament and other structures
 - Predisposing factors
 - Obese, middle-aged women
 - Employment in occupations involving repetitious motions of the fingers and hands



Figure 44-38



(From Thompson, J.M., et al. [2002]. *Mosby's clinical nursing*. [5th ed.]. St. Louis: Mosby.)

A, Wrist structures involved in carpal tunnel syndrome. **B**,
Decompression of median nerve.



Traumatic Injuries

- Carpal tunnel syndrome (*continued*)
 - Clinical manifestations/assessment
 - Paresthesia
 - Hypoesthesia
 - Burning pain or tingling in the hands
 - Inability to grasp or hold small objects
 - Edema of the hand, wrist, or fingers
 - Muscle atrophy
 - Depressed appearance at the base of the thumb on the palmar side



Traumatic Injuries

- Carpal tunnel syndrome (*continued*)
 - Diagnostic tests
 - Physical exam—Tinel's sign
 - Electromyogram
 - MRI
 - Medical management/nursing interventions
 - Immobilizer
 - Elevate extremity
 - ROM exercises
 - Hydrocortisone injections
 - Surgery

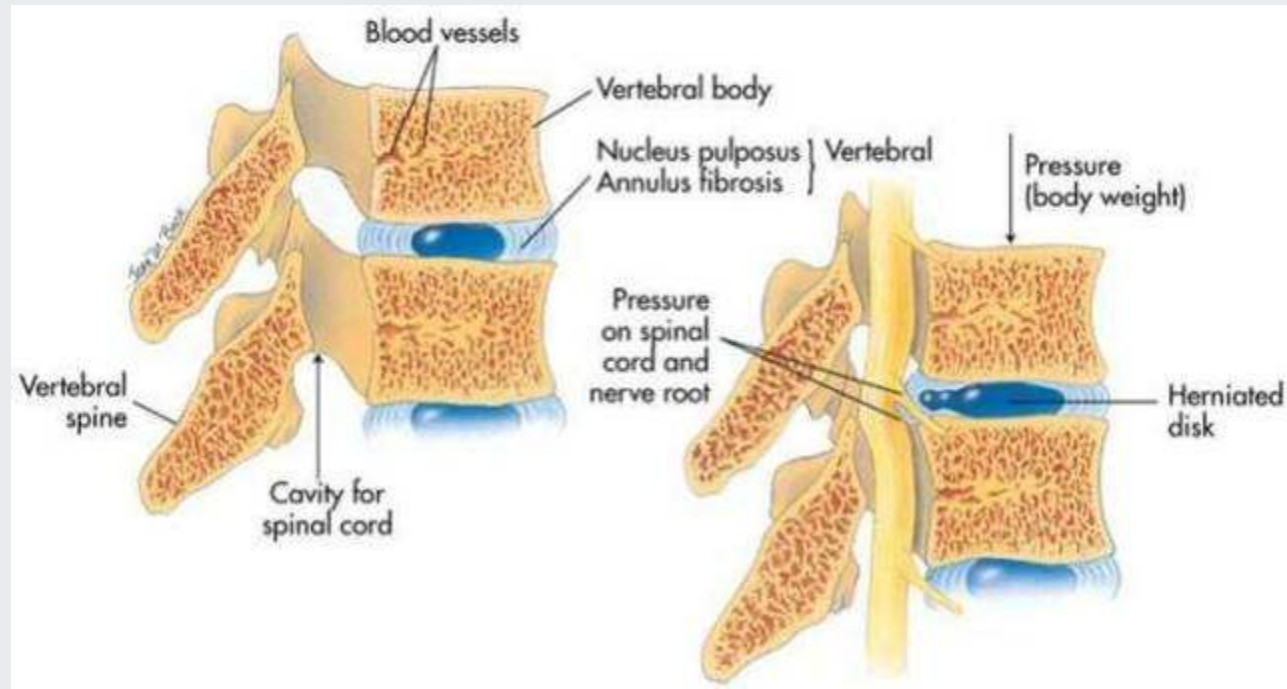


Traumatic Injuries

- Herniation of intervertebral disk
 - Etiology/pathophysiology
 - Rupture of the fibrocartilage surrounding an intervertebral disk, releasing the nucleus pulposus that cushions the vertebrae above and below
 - Lumbar and cervical herniations are most common
 - May occur from lifting, twisting, trauma, or degenerative changes



Figure 44-39



(From Thibodeau, G.A., Patton, K.T. [2005]. *The human body in health and disease*. [4th ed.]. St. Louis: Mosby.)

Sagittal section of vertebrae showing both normal and herniated disks.



Traumatic Injuries

- Herniation of intervertebral disk (*continued*)
 - Clinical manifestations/assessment
 - Lumbar
 - Low back pain that radiates over the buttock and numbness and tingling in affected leg
 - Cervical
 - Neck pain, headache, and neck rigidity
 - Diagnostic tests
 - CAT scan, myelography, and electromyelography



Traumatic Injuries

- Herniation of intervertebral disk (*continued*)
 - Medical management/nursing interventions
 - Pharmacological management
 - Analgesics
 - Muscle relaxants
 - Bed rest
 - Physical therapy
 - Traction
 - Surgery
 - Laminectomy, spinal fusion, diskectomy, chemonucleolysis



Tumors

- Tumors of the bone
 - Etiology/pathophysiology
 - May be primary or secondary
 - Benign or malignant
 - Osteogenic sarcoma
 - Osteochondroma
 - Clinical manifestations/assessment
 - Spontaneous fractures
 - Anemia
 - Pain especially with weight-bearing
 - Edema and discoloration of skin at site



Tumors

- Tumors of the bone (*continued*)
 - Diagnostic tests
 - Radiography studies
 - Bone scan; bone biopsy
 - CBC; platelet count; serum protein levels
 - Serum alkaline phosphatase level
 - Medical management/nursing interventions
 - Surgery
 - Chemotherapy and radiation

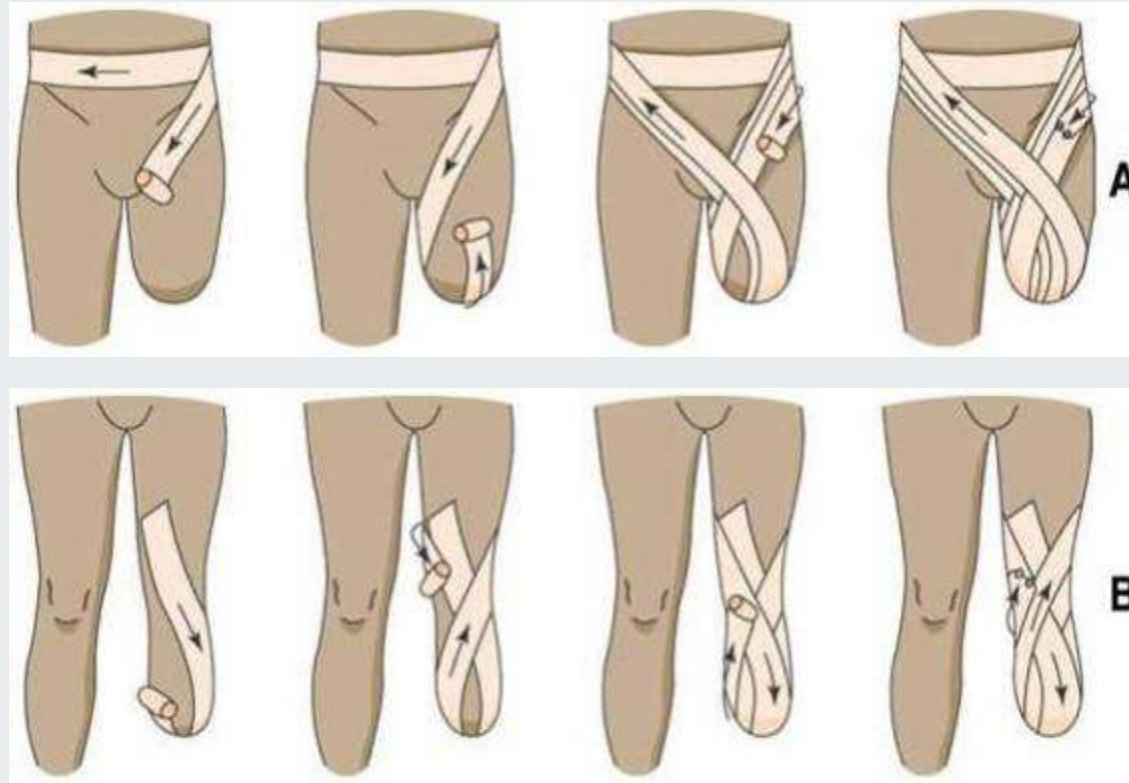


Amputation

- Amputation of a portion of or an entire extremity
 - Malignant tumors, injuries, impaired circulation, congenital deformities, infections
- Postoperative nursing interventions
 - Raise foot of bed to elevate extremity
 - Encourage movement
 - Place in prone position at least two times a day
 - Teach strengthening exercises
 - Elastic wraps to shape residual extremity
 - Assess for respiratory complications
 - Phantom-limb pain is normal



Figure 44-40



(From Beare, P.G., Myers, J.L. [1998]. *Adult health nursing*. [3rd ed.]. St. Louis: Mosby.)

Correct method of bandaging amputation stump.



Nursing Process

- Assessment
 - Scoliosis
 - Lateral curvature of the spine
 - Kyphosis
 - A rounding of the thoracic spine
 - Hump-backed appearance
 - Lordosis
 - An increase in the curve at the lumbar region
 - Blanching test
 - Capillary nail refill



Nursing Process

- Nursing diagnoses
 - Mobility, impaired physical
 - Mobility, impaired bed
 - Coping, ineffective
 - Anxiety
 - Pain
 - Knowledge, deficient